

Allergic Rhinitis

Ni Luh Eka Damayanti

Simpang Raya Public Health Centre, Indonesia

niluheka.damayanti@yahoo.com

Article Information

Submitted: 07 September
2023

Accepted: 11 September
2023

Online Publish: 20
September 2023

Abstract

Allergic rhinitis (AR) is a common chronic illness worldwide, characterized by immunoglobulin E (IgE)-mediated reactions to inhaled allergens. Allergic rhinitis (AR) frequently presents alongside asthma and conjunctivitis, and it is a significant global health issue that imposes a substantial burden and handicap on a global scale. The classification of Allergic Rhinitis (AR) into intermittent or chronic and mild or moderate/severe was established by the Allergic Rhinitis and its Impact on Asthma (ARIA) program. The diagnosis is established through a comprehensive assessment of the patient's clinical history, thorough physical examination, and appropriate diagnostic tests. The pharmacological treatments most employed consist of oral, intranasal, or ocular H1-antihistamines, intranasal corticosteroids, or a set combination of intranasal H1-antihistamines and corticosteroids.

Keyword: *Allergic Rhinitis; Immune Cells; Allergic; Allergen Immunotherapy;*

Introduction

Allergic rhinitis (AR) is characterized by an immunological response facilitated by IgE antibodies inside the nasal mucosa, which is initiated upon exposure to allergens present in the air. The illness under consideration is characterized by symptoms including the presence of watery nasal discharge (rhinorrhea), nasal obstruction, sneezing, and nasal itching. Furthermore, there may be an association between these manifestations and the presence of itching in the ocular region, as well as the mouth and throat (Dhingra & Dhingra, 2021)

In addition to exhibiting nasal symptoms, individuals diagnosed with allergic rhinitis (AR) may also manifest related allergic conjunctivitis, non-productive cough, Eustachian tube dysfunction, and chronic sinusitis (Dhingra & Dhingra, 2021). Upon receiving a diagnosis, allergic rhinitis (AR) can be effectively managed using a range of treatment methods. The initial approach often involves the use of intra-nasal glucocorticoids as the primary therapeutic intervention (Wise et al., 2023)

Definition

Allergic rhinitis (AR) is a type I hypersensitivity response of the nasal mucosal membranes, mediated by immunoglobulin E (IgE). This condition occurs when a sensitized individual is exposed to an allergen. The condition is symptomatically defined by the presence of anterior or posterior rhinorrhea, nasal congestion or congestion, nasal pruritis, and sneezing (Wise et al., 2023). The condition known as AR is highly frequent and can lead to notable physical consequences including the onset of recurring or persistent morbidities. Moreover, there is a significant correlation between this condition and asthma, providing further evidence for the unified airway theory (Bousquet et al., 2020)

Etiology

During the initial stage, allergic rhinitis is characterized by an immune response mediated by immunoglobulin (Ig)E against inhaled allergens, resulting in inflammation mostly influenced by type 2 helper (Th2) cells. The onset of the initial response often takes place within a timeframe of five to 15 minutes after the individual's exposure to an antigen. This leads to the degranulation of mast cells present in the host organism (Casale & Bousquet, 2021)

This process results in the release of a diverse range of pre-existing and newly produced mediators, such as histamine, which plays a significant role as a mediator in allergic rhinitis. Histamine elicits sneeze through activation of the trigeminal nerve and additionally contributes to rhinorrhea by promoting the secretion of mucous glands. In addition to their involvement in immunological responses, leukotrienes and prostaglandins have been identified as potential contributors to nasal congestion due to their ability to induce vascular changes in blood vessels. The late-phase reaction is characterized by the release of cytokines, specifically interleukins (IL)-4 and IL-13, from mast cells approximately four to six hours after the initial response. The aforementioned

cytokines play a role in promoting the migration of eosinophils, T-lymphocytes, and basophils into the nasal mucosa, leading to the development of nasal edema and subsequent congestion (Bousquet et al., 2020)

Epidemiology

With a frequency of up to 50% in some nations, AR is one of the most prevalent chronic diseases in high-income countries. In contrast, the number of cases of the disorder in question is comparatively lower in countries with middle to low incomes (Bousquet et al., 2020). However, it is important to note that the prevalence in these nations is constantly on the rise. Antimicrobial resistance (AR) is a pervasive global health issue that imposes a significant burden and contributes to disability on a global scale (Casale & Bousquet, 2021)

Allergic rhinitis affects an estimated 10% to 20% of the American population, resulting in an annual expenditure of \$4.9 billion within the US healthcare system. Indirect costs can exacerbate this burden by contributing to lost productivity, delayed or inaccurate diagnoses, excessive prescription practices, or the emergence of secondary consequences (Akhouri & House, 2019)

It is imperative to approach this matter with a certain level of uncertainty, as the clinical diagnosis of allergic rhinitis is subject to several diagnostic alternatives that can potentially impact the data provided in numerous epidemiological studies (Schuler IV & Montejo, 2021)

Risk factors associated with the development of allergic rhinitis (AR) encompass a familial predisposition towards atopy, male gender, the presence of allergen-specific immunoglobulin E (IgE), a serum IgE level surpassing 100 IU/mL prior to the age of 6, and a higher socioeconomic standing. Research conducted on young children has indicated an increased susceptibility to allergic rhinitis (AR) among individuals who were introduced to meals or formula at an early age and/or experienced significant exposure to cigarette smoke during their first year of life.

Despite numerous recent research that have examined the relationship between pollution and the onset of allergic rhinitis (AR), a substantial correlation has not yet been established. It is noteworthy that multiple factors have been identified which could exert a protective influence on the progression of allergic rhinitis (AR) (Czech et al., 2023)

The impact of breastfeeding on the development of allergic rhinitis (AR) is a subject of ongoing research discussion. Still, it continues to be approved as a recommended practice owing to its well-established benefits and avoidance of any linked negative side effects (Schuler IV & Montejo, 2021)

Classification

The classification of seasonal and persistence allergic rhinitis may give rise to potential conflicts. For instance, the persistence of seasonal allergic rhinitis (AR) may be extended due to the impacts of climate change, leading to protracted increases in pollen levels (Bousquet et al., 2020)

The phenomenon of seasonal allergic rhinitis may persist throughout numerous seasons due to the development of sensitivity to multiple allergens. Moreover, it should be noted that indications of persistent allergies may not occur consistently over the entirety of the year. This phenomenon is especially observed in patients who have an allergic reaction to house dust mites (HDM), as they may exhibit mild or moderate/severe intermittent allergic rhinitis (AR) (Zhang et al., 2021)

The ARIA organization has put out a novel approach to categorization, which considers the duration and consistency of symptoms. Intermittent allergic rhinitis is characterized by symptoms occurring for fewer than four days per week or for a duration of less than four consecutive weeks. Persistent allergic rhinitis is defined as the presence of symptoms for a duration of more than four days per week, consistently persisting for a minimum of four consecutive weeks (Bousquet et al., 2020)

Furthermore, it has been shown that the existing classifications of seasonal and persistent allergic rhinitis (AR) are not compatible with the proposed classification of intermittent/persistent AR, as they do not encompass the same categorization of the illness condition (Akhouri & House, 2019)

Therefore, it should be noted that intermittent allergic rhinitis (AR) and persistent AR should not be considered equivalent to seasonal and perpetual classifications. The ARIA guidelines have also suggested a new categorization of severity (mild and moderate-severe) in relation to these problems. allergic rhinitis (AR) has the potential to give rise to problematic symptoms, such as disruptions in sleep patterns, limitations in everyday, recreational, or athletic pursuits, hindrances in academic or professional performance, or the occurrence of bothersome symptoms. allergic rhinitis (AR) is regarded as mild if none of the events take place. If an individual experiences one or more of these symptoms, allergic rhinitis (AR) is categorized as mild to severe (Bousquet et al., 2020)

Pathophysiology

The investigation of nasal allergic reactions, symptom monitoring, and the collection of nasal secretions, serum for mediator measures, as well as nasal scrapings or biopsy from patients, can be facilitated through allergen exposure, whether administered topically intranasally or within an exposure chamber (Bousquet et al., 2020). Furthermore, various stimuli and interventions can be employed to study blood cells, including basophils and antigen-specific T lymphocytes, as well as nasal mucosa tissue, in an ex vivo setting (Zhang et al., 2021)

The nasal mucosa serves as the principal air conditioning system for the respiratory tract and acts as the initial barrier against airborne pathogens. In order to fulfill these functions, it is important to uphold and reinstate the integrity of the epithelial layer, as well as possess the capacity to trigger immunological responses (Bousquet et al., 2020)

When the epithelium is exposed to conditions or factors that compromise the integrity of the mucosal layer, it responds by releasing alarmins and other damage-associated molecular patterns. These molecules serve to launch repair mechanisms, but

they can also trigger a protective inflammatory response. In the realm of augmented reality (AR), it is plausible that identical mechanisms could be at play in the initiation of disease (Akhouri & House, 2019)

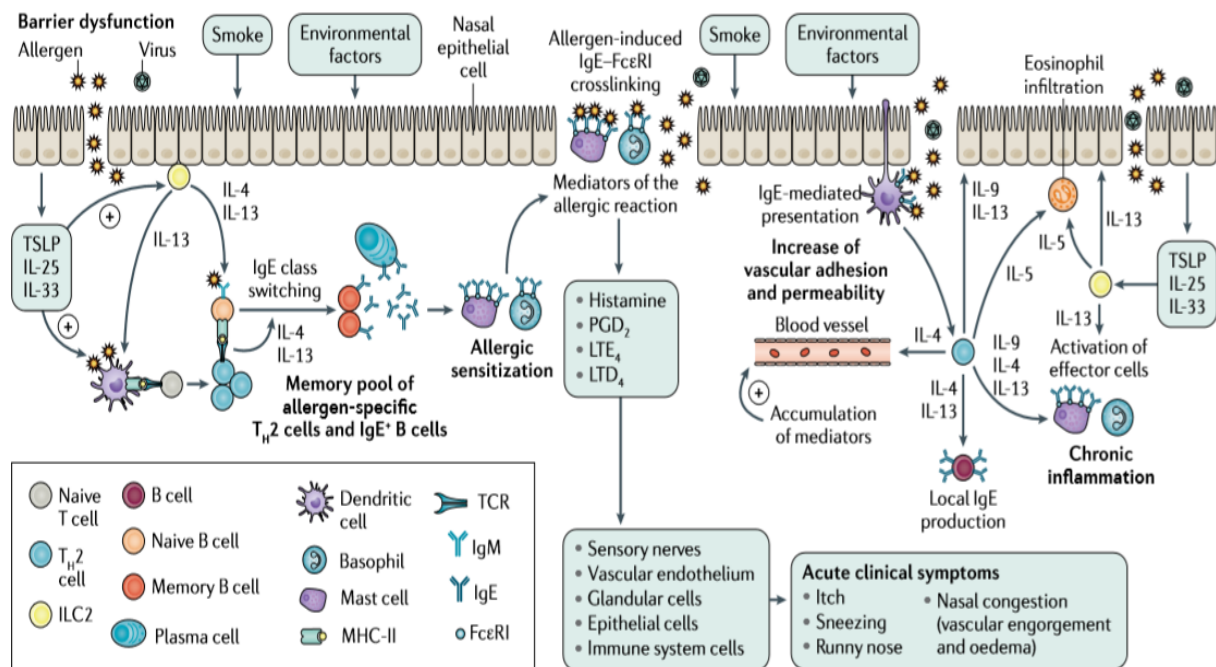


Figure 1 Pathophysiology of allergic rhinitis

In the sensitization phase, dendritic cells located in the nasal mucosa uptake allergens and initiate a cascade of processes that ultimately result in the production of plasma cells. These plasma cells are responsible for generating allergen-specific immunoglobulin E (IgE), which subsequently binds to mast cells and basophils. Additionally, a population of memory allergen-specific type 2 T helper cells (TH2 cells) and IgE+ B cells is formed. Upon contact to the allergen, people who have developed sensitivity exhibit activation of basophils and mast cells inside the nasal mucosa (Bousquet et al., 2020). This activation subsequently induces the production of allergic mediators, such as histamine and self-deceptive leukotrienes. Consequently, these mediators contribute to the manifestation of acute symptoms associated with allergic rhinitis (Akhouri & House, 2019)

Diagnosis

The diagnosis of allergic rhinitis (AR) is established through a comprehensive evaluation that includes a thorough patient history, backed by findings from physical examination and, if deemed required, nasal endoscopy. Additionally, testing for allergen-specific immunoglobulin E (IgE) may be conducted if warranted (Burte et al., 2020). Additional diagnostic procedures, such as nasal allergen challenge, CT scans, assessment of nasal nitric oxide and ciliary beat frequency, nasal smears, nasal cultures, and analysis

of nasal fluid for β -transferrin, may be necessary to confirm or rule out various types of rhinitis (Wise et al., 2023)

Clinical history

The clinical history should comprehensively document symptoms, with a special focus on those that significantly impact the patient's well-being (Bousquet et al., 2020). Additionally, it should include detailed information regarding the location and timing of symptom occurrence, as well as any circumstances that worsen or alleviate the symptoms. It is important to document additional symptoms experienced in the chest, ears, throat, gut, or skin, as well as any relevant patient or family history of allergic disease and/or immunological disorders. Additionally, a comprehensive assessment should include a thorough evaluation of previously attempted therapies, current medications, and their effectiveness (Sarhan et al., 2021)

Rhinitis is a condition that is widely recognized by persons due to its association with the common cold. Rhinitis is clinically defined as the presence of at least two of the following symptoms, namely nasal running, nasal blocking, nasal itching, or sneezing, persisting for a duration exceeding one hour each day (Czech et al., 2023)

The appropriate diagnosis of this condition is typically achieved through a thorough examination of the patient's medical history. However, it is important to note that there is a potential for misdiagnosis due to certain misconceptions. For instance, symptoms may be mistakenly attributed to common colds, larger adenoids in mouth-breathing youngsters may be incorrectly identified as the cause, and secretions passing posteriorly may go unnoticed. It is advisable to conduct inquiries with asthma patients regarding their nasal functionality, encompassing their capacity to respire through the nose and perceive odors. This is crucial due to the high prevalence of rhinitis or rhinosinusitis among individuals diagnosed with asthma (Czech et al., 2023)

Physical Examination

A comprehensive evaluation of the patient is required due to the significant comorbidities associated with rhinitis. It is imperative to evaluate the growth of children, as there is a correlation between diminished growth and the presence of serious airway issues. Moreover, the concurrent administration of intranasal corticosteroids (INCS) and inhaled corticosteroids (ICS) may potentially lead to a decrease in height, particularly when administered at high dosages (Bousquet et al., 2020)

The identification of facial characteristics such as conjunctivitis, nasal allergic crease, allergic salute, or double creases beneath the eyes (known as Dennie-Morgan lines) all indicate the existence of an allergic diathesis in the patient. A nasal examination is indicated for patients presenting with moderate to severe allergic rhinitis (AR) or for those who continue to experience uncontrolled symptoms while receiving appropriate treatment. The evaluation should encompass an appraisal of the outside physical characteristics, followed by an inside examination, ideally utilizing a Nas endoscope.

In the examination of pediatric patients, the utilization of an otoscope may be deemed adequate for the purpose of assessing the nasal cavity (Orlandi et al., 2021). It is important to observe and document the location of the nasal septum, as well as the dimensions and pigmentation of the inferior turbinate. Additionally, one should assess the condition of the mucosa, and identify any secretions, polyps, bleeding, tumors, crusting, or foreign objects present (Patel et al., 2022)

Patients with allergic rhinitis (AR) often have a characteristic presentation of the nasal cavity, which includes inflated, pale, and bluish inferior turbinate's accompanied by abundant clear secretions (Patel et al., 2022). However, it is important to note that the nasal appearance may appear normal in some cases, and these traits are not exclusive to AR. It is worth mentioning that individuals who use intranasal corticosteroids (INCS) may have a mild reddening of the mucosa. It is recommended that patients exhibiting symptoms such as nasal polyps, bleeding, unilateral disease, excessive crusting, and septal perforations be sent to an ear, nose, and throat specialist (Hox et al., 2020). The occurrence of high crusting and septal perforations is primarily associated with prior septal surgery however it can also manifest in cases of cocaine usage and vasculitis's (Scadding & Scadding, 2021)

Test

The identification of allergens by the use of skin prick or blood tests to measure allergen-specific IgE levels is a necessary step in confirming a diagnosis and is essential when considering allergy immunotherapy (AIT) as a treatment option. (Bousquet, 2020) It is important to consider the clinical history when interpreting the findings of IgE testing, as there is a possibility of both false-positive and false-negative results. A meta-analysis conducted on skin prick tests revealed a range of sensitivity between 68% and 100%, while specificity varied between 70% and 91% (Bousquet et al., 2020)

Other procedures that can be conducted include nasal allergen challenge, nasal cytology, nasal nitric oxide measures, and ciliary beat frequency analysis. The practice of nasal smear cytology is implemented in select centers (Patel et al., 2022) (Krzych-Fa ta et al., 2022)

The observation of a significant quantity of eosinophils, although the specific threshold for their presence is subject to debate, indicates the occurrence of an inflammatory mechanism, without necessarily indicating the presence of AR (allergic rhinitis) or non-allergic rhinitis with eosinophilia. It is plausible that the latter condition, if present, would respond well to corticosteroid treatment. The occurrence of unilateral eosinophilia necessitates the collection of bilateral samples (Krzych-Fa ta et al., 2022)

The measurement of nasal nitric oxide is a straightforward and expeditious examination that effectively distinguishes between allergic rhinitis, non-allergic rhinitis, and their respective subgroups, with satisfactory levels of sensitivity and specificity. However, it is important to note that this test can only be conducted in specialist centers with a high level of expertise (Czech et al., 2023)

Differential Diagnosis

The differential diagnosis for allergic rhinitis encompasses other non-allergic forms of rhinitis. It is important to evaluate children, especially those who are younger than 2 years old, for congenital factors that may contribute to nasal obstruction, which include choanal atresia and immunodeficiencies (Scadding & Scadding, 2021)

The other condition refers to differential diagnosis of allergic rhinitis include *vasomotor rhinitis*, is a form of noninflammatory rhinitis that can be induced by alterations in temperature, olfactory stimuli, or humidity levels. *Infectious rhinitis*, a condition characterized by viral or bacterial infections, is predominantly observed in the pediatric population (Akhouri & House, 2019)

The individual presents with a *cerebrospinal fluid leak*, which is characterized by clear/serous rhinitis that has proven to be unresponsive to treatment. *Non-allergic rhinitis with eosinophilia syndrome* (NARES) refers to the presence of eosinophils infiltrating nasal tissue in the absence of allergic sensitization. *Chemical rhinitis* refers to the condition when individuals are exposed to various chemicals either through their profession, household chemicals, or during sport and leisure activities. *Rhinitis of pregnancy*, also known as hormonally-induced rhinitis, is a condition characterized by inflammation of the nasal passages during pregnancy (Krzych-Falta et al., 2022)

Drug-induced rhinitis/ rhinitis medicamentosa, such as that caused by nonsteroidal anti-inflammatory drugs (NSAIDs), angiotensin-converting enzyme (ACE) inhibitors, nasal decongestants, and cocaine. *Autoimmune, granulomatous, and vasculitic rhinitis* are medical conditions that encompass many disorders such as Granulomatosis with polyangiitis and sarcoidosis. *Nasal polyposis* refers to the presence of polyps within the nasal cavity (Akhouri & House, 2019)

A nasopharyngeal neoplasm refers to a tumor that develops in the upper nasopharynx. In the case of a young child who exhibits *nasal polyp* and well-managed *asthma*, the recommended course of action to exclude the possibility of *cystic fibrosis* is to proceed with sweat chloride testing. It can be determined by clinical findings and several tests, even signs and symptoms related to each other but the management depends on the pathogenesis of the disease (Akhouri & House, 2019)

Management

The management strategies for allergic rhinitis (AR) encompass several approaches, such as patient education, allergen avoidance, medication, and allergen immunotherapy (AIT). Pharmacotherapy has been shown to be efficacious in most patients and, when performed appropriately, enhances quality of life. Nevertheless, a significant proportion of patients exhibit noncompliance with prescribed medications, resulting in poor adherence to pharmacotherapy. Currently, there is only one biologic, omalizumab, that has received approval for the treatment of allergic rhinitis (AR) specifically for *Cryptomeria japonica* allergy in Japan. Due to the high costs associated with biologics and the widespread occurrence of AR, it is possible that newly developed

biologics may be limited to a select group of patients with severe AR who meet specific criteria (Wise et al., 2023)

Avoidance – house dust mite (HDM) (Level of Evidence B)

There exists additional proof about the efficacy of acaricides in diminishing the concentration of house dust mites (HDM) in children who concurrently experience allergic rhinitis (AR) and asthma. In individuals who do not have concurrent asthma, the utilization of acaricides, either alone or in combination with bedroom-based control programs, shows potential for reducing the concentration of house dust mites (HDM) (Wise et al., 2023). However, additional rigorous studies are necessary to assess the impact of these interventions on clinical outcomes (Bousquet et al., 2020)

Avoidance – occupational (Level of Evidence C)

The potential benefits of reducing allergen exposure include a decrease in symptoms, an improvement in quality of life, and a potential decrease in the risk of developing occupational asthma (Wise et al., 2023)

Pharmacotherapy and procedural options

Oral H₁ antihistamines (Level of Evidence A)

The treatment of allergic rhinitis may include the consideration of newer-generation oral antihistamines. The use of first-generation oral antihistamines is not advised for the management of allergic rhinitis due to their associated central nervous system and anticholinergic adverse effects. In comparison to first-generation oral antihistamines, newer-generation antihistamines exhibit a reduced incidence of central nervous system and anticholinergic adverse effects. The older population may experience more noticeable adverse effects when using first-generation antihistamines (Wise et al., 2023)

Oral H₂ antihistamines (Level of Evidence B)

Four studies have demonstrated that the combination of H₂ antagonists with H₁ antagonists resulted in a decrease in objective nasal resistance and an improvement in symptom control. The potential enhancement of symptom control in allergic rhinitis (AR) through the substitution of an oral H₂ antagonist with an oral H₁ antagonist has been suggested, but the available data is currently limited. There is a lack of trials assessing the effectiveness of H₂ antihistamines in the setting of intranasal corticosteroids (INCS). Two investigations have demonstrated that there is no observed advantage in using H₂ antagonists either independently or as a supplement to H₁ antagonist therapy (Wise et al., 2023)

Intranasal antihistamines (Level of Evidence A)

In the treatment of allergic rhinitis, intranasal antihistamines can be utilized as either primary or secondary treatment options. The efficacy of intranasal antihistamine as a monotherapy has repeatedly been found to be superior to that of placebo (Wise et al.,

2023). Most of the research indicate that intranasal antihistamines are more effective than intranasal corticosteroids (INCS) in alleviating symptoms such as sneezing, itching, rhinorrhea, and ocular discomfort. The occurrence of adverse effects is minimal and occurs with low frequency. There is already a wide range of both generic prescription and over-the-counter preparations that are readily accessible (Peng et al., 2020)

Intranasal saline (Level of Evidence A)

Nasal saline is recommended as a first therapeutic option for individuals with allergic rhinitis (AR), either as independent therapy or in conjunction with other pharmacological treatments, since research indicates an additional beneficial impact. There is a possibility that hypertonic saline may exhibit greater efficacy in pediatric patients. The available data does not provide solid evidence about the optimal levels of salinity, buffering, and the frequency and amount of administration (Wise et al., 2023)

Oral corticosteroids (Level of Evidence B)

Oral steroids may be an acceptable option for certain individuals who experience severe nasal blockage that hinders the effective delivery of intranasal medications, such as corticosteroids or antihistamines. In these instances, the administration of a brief regimen of systemic corticosteroids has the potential to ameliorate congestion and enhance the effectiveness of topical medications. There is a lack of data to support this claim, hence it is recommended to exercise cautious clinical judgment and engage in thorough risk discussion (Wise et al., 2023)

Intranasal corticosteroid sprays (Level of Evidence A)

Nasal corticosteroid spray (NCS) has demonstrated efficacy in reducing both nasal and ocular symptoms associated with allergic rhinitis (AR). Several studies have indicated that the efficacy of certain treatments is higher when compared to oral anti-histamines and leukotriene receptor antagonists (LTRAs)

Oral decongestants (Level of Evidence B)

While it is not advisable to routinely use pseudoephedrine in the treatment of allergic rhinitis (AR), it can be efficacious in decreasing nasal congestion in AR patients. Nevertheless, its usage should be limited to short-term or emergency treatment, following a comprehensive interaction with the patient regarding the potential risks and benefits, considering any existing comorbidities, and exploring alternative intranasal therapy options

Intranasal decongestants (Level of Evidence B)

In the context of alleviating nasal congestion, intranasal decongestants have demonstrated efficacy in providing temporary relief. An alternative suitable for temporary utilization. In individuals experiencing an acute flare of allergic rhinitis (AR), intranasal decongestants have been found to offer effective short-term relief from nasal congestion.

However, it is not recommended to use these decongestants regularly due to the potential danger of developing rhinitis medicamentosa

Complications

Chronic rhinosinusitis, despite being a separate condition from allergic rhinitis, has the potential to develop because of allergic rhinitis. The condition is distinguished by inflammation of the nasal passages, presenting symptoms of prolonged nasal congestion or discharge lasting beyond a duration of three months (Prieto et al., 2021)

Nasal polyposis, a manifestation of chronic rhinosinusitis, arises due to the persistent inflammation of the mucosa in the paranasal sinuses. Nasal polyps are commonly non-malignant in nature and tend to manifest bilaterally. The presence of unilateral nasal polyps should elicit concerns regarding the possibility of cancer. The prevalence of nasal polyps within the general population is estimated to be around 4%, with a higher occurrence observed among males. The available treatment modalities encompass the use of topical steroids as well as saline irrigation. The procedure of surgical removal is often limited to patients who have not shown an adequate reaction to medicinal therapy (Terada & Kawata, 2022)

Prognosis

It is generally accepted that the incidence of allergic rhinitis reaches its highest point during adolescence and afterwards declines progressively as individuals mature. In the context of a longitudinal study, it was observed that during the 23-year follow-up period, most patients, specifically 54.9%, exhibited a positive change in their symptoms. Among this group, 41.6% achieved complete remission and were no longer experiencing any symptoms. There was a higher likelihood of improvement observed in patients who had the onset of symptoms at a younger age.

The severity of allergic rhinitis (AR) exhibits temporal variability and is contingent upon a multitude of factors, including geographical location and seasonal variations. Around half of the patients who had grass allergy immunotherapy experienced a notable amelioration in their symptoms, which persisted for a duration of three years following the cessation of the treatment (Wise et al., 2023)

References

- Akhouri, S., & House, S. A. (2019). *Allergic rhinitis*.
- Bousquet, J., Anto, J. M., Bachert, C., Baiardini, I., Bosnic-Anticevich, S., Walter Canonica, G., Meln, E., Palomares, O., Scadding, G. K., & Togias, A. (2020). Allergic rhinitis. *Nature Reviews Disease Primers*, 6(1), 95.
- Burte, E., Leynaert, B., Marcon, A., Bousquet, J., Benmerad, M., Bono, R., Carsin, A.-E., de Hoogh, K., Forsberg, B., & Gormand, F. (2020). Long-term air pollution exposure is associated with increased severity of rhinitis in 2 European cohorts. *Journal of Allergy and Clinical Immunology*, 145(3), 834–842.
- Casale, T. B., & Bousquet, J. (2021). Allergen Immunotherapy: A Long Way Gone and a Long Way to Go. *The Journal of Allergy and Clinical Immunology: In Practice*, 9(5), 1839–1840.
- Czech, E. J., Overholser, A., & Schultz, P. (2023). Allergic Rhinitis. *Primary Care: Clinics in Office Practice*, 50(2), 159–178.
- Dhingra, P. L., & Dhingra, S. (2021). *Diseases of Ear, Nose & Throat and Head & Neck Surgery-E-Book*. Elsevier Health Sciences.
- Hox, V., Lourijsen, E., Jordens, A., Aasbjerg, K., Agache, I., Alobid, I., Bachert, C., Boussery, K., Campo, P., & Fokkens, W. (2020). Benefits and harm of systemic steroids for short-and long-term use in rhinitis and rhinosinusitis: an EAACI position paper. *Clinical and Translational Allergy*, 10, 1–27.
- Krzych-Fa ta, E., Wojas, O., Samoli ski, B. aw K., Majsiak, E., Bia ek, S. awomir, & Lishchuk-Yakymovych, K. (2022). Gold standard diagnostic algorithm for the differential diagnosis of local allergic rhinitis. *Advances in Dermatology and Allergology/Post Py Dermatologii i Alergologii*, 39(1), 20–25.
- Orlandi, R. R., Kingdom, T. T., Smith, T. L., Bleier, B., DeConde, A., Luong, A. U., Poetker, D. M., Soler, Z., Welch, K. C., & Wise, S. K. (2021). International consensus statement on allergy and rhinology: rhinosinusitis 2021. *International Forum of Allergy & Rhinology*, 11(3), 213–739.
- Patel, Z. M., Holbrook, E. H., Turner, J. H., Adappa, N. D., Albers, M. W., Altundag, A., Appenzeller, S., Costanzo, R. M., Croy, I., & Davis, G. E. (2022). International consensus statement on allergy and rhinology: Olfaction. *International Forum of Allergy & Rhinology*, 12(4), 327–680.
- Peng, Y.-Q., Qin, Z.-L., Fang, S.-B., Xu, Z.-B., Zhang, H.-Y., Chen, D., Liu, Z., Bellanti, J. A., Zheng, S. G., & Fu, Q.-L. (2020). Effects of myeloid and plasmacytoid dendritic cells on ILC2s in patients with allergic rhinitis. *Journal of Allergy and Clinical Immunology*, 145(3), 855–867.
- Prieto, A., Rondn, C., Eguiluz Gracia, I., Muoz, C., Testera Montes, A., Bogas, G., Nuñez Cuadros, E., Campo, P., & Torres, M. J. (2021). Systematic evaluation of allergic phenotypes of rhinitis in children and adolescents. *Pediatric Allergy and Immunology*, 32(5), 953–962.

- Sarhan, R. M., Mohammad, M. F., & Boshra, M. S. (2021). Differential clinical diagnosis and prevalence rate of allergic rhinitis, asthma and chronic obstructive pulmonary disease among COVID 19 patients. *International Journal of Clinical Practice*, 75(10), e14532.
- Scadding, G. K., & Scadding, G. W. (2021). Innate and adaptive immunity: ILC2 and Th2 cells in upper and lower airway allergic diseases. *The Journal of Allergy and Clinical Immunology: In Practice*, 9(5), 1851–1857.
- Schuler IV, C. F., & Montejo, J. M. (2021). Allergic rhinitis in children and adolescents. *Immunology and Allergy Clinics*, 41(4), 613–625.
- Terada, T., & Kawata, R. (2022). Diagnosis and treatment of local allergic rhinitis. *Pathogens*, 11(1), 80.
- Wise, S. K., Damask, C., Roland, L. T., Ebert, C., Levy, J. M., Lin, S., Luong, A., Rodriguez, K., Sedaghat, A. R., & Toskala, E. (2023). International consensus statement on allergy and rhinology: Allergic rhinitis 2023. *International Forum of Allergy & Rhinology*, 13(4), 293–859.
- Zhang, Y., Lan, F., & Zhang, L. (2021). Advances and highlights in allergic rhinitis. *Allergy*, 76(11), 3383–3389.

Copyright holder:

Ni Luh Eka Damayanti (2023)

First publication right:

KESANS: International Journal Health and Science

This work is licensed under a Creative Commons Attribution-ShareAlike 4.0
International License

